

“Re: Radiation protection in pediatric radiology”

Haluk Söylemez · Ahmet Ali Sancaktutar ·
Bulent Altunoluk · Murat Atar

Received: 6 February 2012 / Accepted: 11 February 2012 / Published online: 25 February 2012
© Springer-Verlag 2012

Dear Sir,

I read the article by Alzen and Benz-Bohm with great interest [1]. This study is a valuable contribution to the literature which elucidates the protection of pediatric patients from the harmful effects of radiation exposure. Furthermore, they reviewed and presented essential and practical ways for protection.

Presently, endourologic procedures such as retrograde pyelography (RGP), retrograde intrarenal surgery (RIRS), percutaneous nephrolithotomy (PCNL), and extracorporeal shock wave lithotripsy (SWL) are increasing in urology practice and most often rely on fluoroscopy. In these procedures, the patient, surgeon, and participating staff will be exposed to some level of ionizing radiation. Therefore, urologists should undertake protective measures for themselves and patients due to the well-known harmful effects of radiation [2, 3]. Despite this information, we estimated and showed that the protection of staff and patient exposed to radiation was poorly coordinated and awareness of urologists about gonad protection was not satisfactory than expected [4, 5].

H. Söylemez (✉) · A. A. Sancaktutar · M. Atar
Department of Urology, Medical Faculty,
Dicle University, Diyarbakir, Turkey
e-mail: drhaluks@yahoo.com

A. A. Sancaktutar
e-mail: aasancaktutar@gmail.com

M. Atar
e-mail: atarsmail@yahoo.com

B. Altunoluk
Department of Urology, Medical Faculty, Sutcu Imam
University, Kahramanmaraş, Turkey
e-mail: drbulenta@yahoo.com

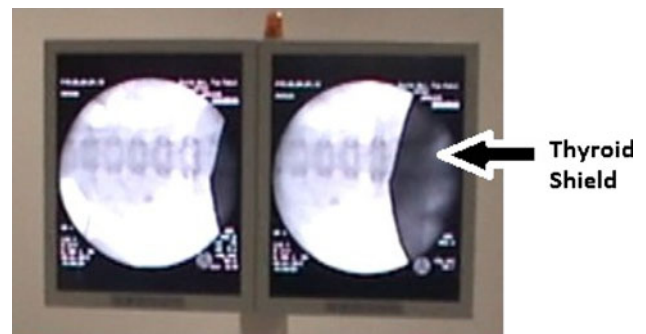

Fig. 1 Fluoroscopic appearance of thyroid shield at pelvic region

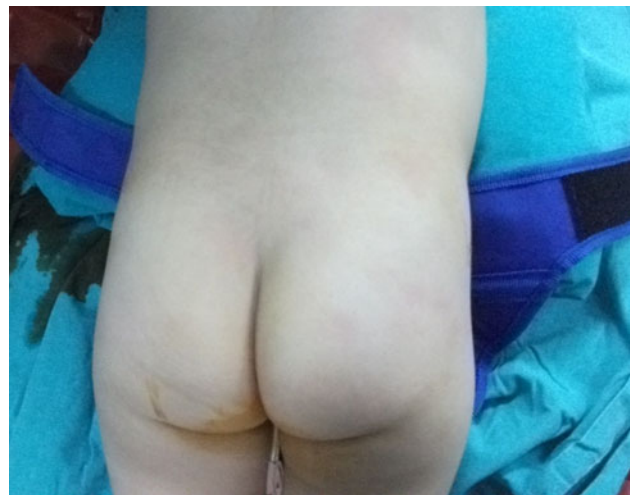


Fig. 2 Thyroid shield is seen under a pediatric patient at prone position

We protect gonads of pediatric patients from radiation exposure by a practical way during endourological procedures, especially in PCNL. The PCNL procedure is performed

under general anesthesia at prone position. Large-sized leaded protective devices are not suitable for pediatric patients during these procedures. Therefore, we use thyroid shields for gonad protection by placing them on the pelvic region (Figs. 1, 2).

We recommend the clinics to use gonad protection especially in pediatric patients. Therefore, they can use thyroid shields for this aim and they can find these materials at their fingertips easily.

References

1. Alzen G, Benz-Bohm G (2011) Radiation protection in pediatric radiology. *Dtsch Arztebl Int.* 108(24):407–414 Epub 2011 Jun 17
2. Linet MS, Kim KP, Miller DL et al (2010) Historical review of occupational exposures and cancer risks in medical radiation workers. *Radiat Res* 174:793
3. Robbins J, Schneider AB (2000) Thyroid cancer following exposure to radioactive iodine. *Rev Endocr Metab Disord* 1:197
4. Söylemez H, Sancaktutar AA, Bozkurt Y, Penbegül N, Atar M, Çakmakçi S (2011) Radiation exposure: does urologist take it seriously? *Eur Urol Suppl* 10(9):604
5. Sancaktutar AA, Atar M, Söylemez H, Bozkurt Y, Penbegül N, Bodakçi MN (2011) Habits and awareness of turkish urologists about using gonad protective. *Eur Urol Suppl* 10(9):578